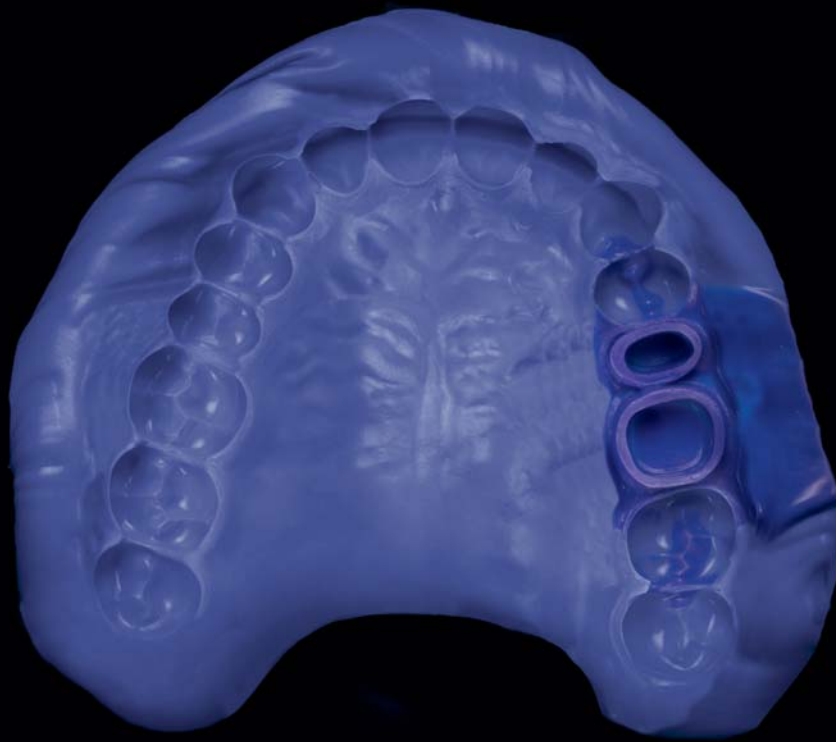



Identium® Medium/Identium® Light in the one-step double mix impression technique

This case history will describe the treatment of a space at tooth 46 (Fig. 1) in a 42-year-old female patient, who decided to have a porcelain fixed partial denture following consultation. Implant treatment was refused because of the augmentation measures required.

After an impression was taken of the upper jaw for the opposing model and block anesthesia of the lower right quadrant, a partial impression was taken of the tooth to be prepared using Silginat® (Kettenbach) for the fabrication of a temporary restoration. During tooth preparation it had to be taken into account that esthetics were an important factor for the patient; it was therefore necessary to prepare a pronounced intrasulcular deep chamfer. After preparation was complete, retraction cords, saturated with ViscoStat (Ultradent), were placed in the sulcus (Fig. 2).

A Rim-Lock tray for taking the impression of the prepared teeth was tried in, cleaned, dried and coated with Identium® Adhesive (Kettenbach) to guarantee reliable retention to the material in the tray (Fig. 3). After the prepared teeth had been cleaned and dried, the retraction cords in the sulcus were removed. Identium® Light was then syringed from an automatic dispensing gun, avoiding entrapping bubbles, onto the prepared teeth starting at the gingiva and moving up to the occlusal. Due to the exceptional hydrophilic properties of Identium® the impression material remains in the sulcus and is

not displaced by the sulcus fluid. The impression tray was loaded at the same time with Identium® Medium from the Plug & Press Dispenser (Kettenbach). The tray was then inserted into the mouth within two minutes, pressed over the dentition from distal to mesial applying light pressure and held in this position.

The odorless and tasteless material does not burden the patient and therefore prevents an excessive gag reflex or saliva flow, which would risk uncontrolled movement and distortion of the impression. After the material had set intraorally, the impression was removed from the patient's mouth as parallel as possible to the axis of the tooth and the result assessed visually under magnifying glasses. The close-ups produced using a macro lens speak for themselves: the details of the intrasulcular preparation are very accurate and perfectly reproduced (Fig. 5 and 6). The impression can be poured immediately. This was followed by the usual bite registration and transfer stages. The porcelain bonded fixed partial denture from 45 to 47 was fitted without requiring any adjustments and fulfilled the functional and aesthetic requirements of the patient.

Conclusion

Use of the new medium viscosity impression material Identium® Medium (here in combination with the low viscosity cartridge material Identium® Light using the one-step double mix technique) provides the following advantages:

- excellent flowability with high positional stability
- outstanding hydrophilicity combined with correspondingly good flow properties
- easy removal from the mouth
- long working time with short intraoral setting time
- odorless and tasteless
- accurately detailed model fabrication without waiting time

The price-performance ratio is excellent and handling is easy in the Plug & Press system, which prevents processing errors.

DR. JÜRGEN WOLZ
 Karlstraße 2, 74072 Heilbronn, Germany
 E-Mail: wolz@roemer-wolz.de

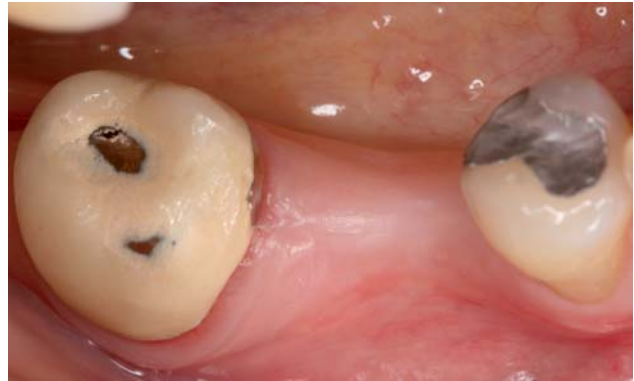

Fig. 1: Initial situation.

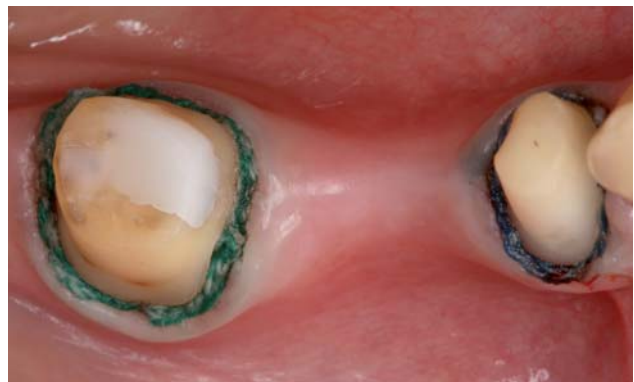

Fig. 2: Prepared teeth with retraction cords.

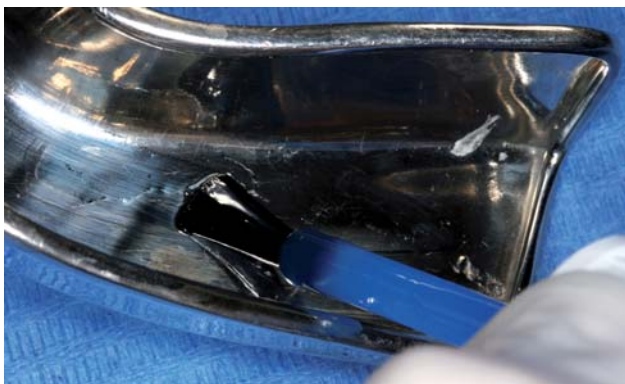


Fig. 3: Application of the adhesive.



Fig. 4: Loading of the tray with Identium® Medium.

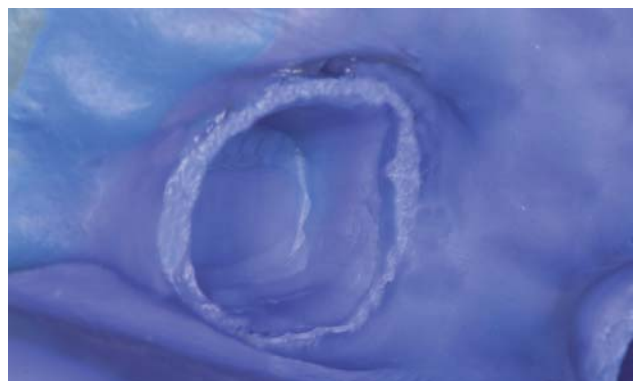
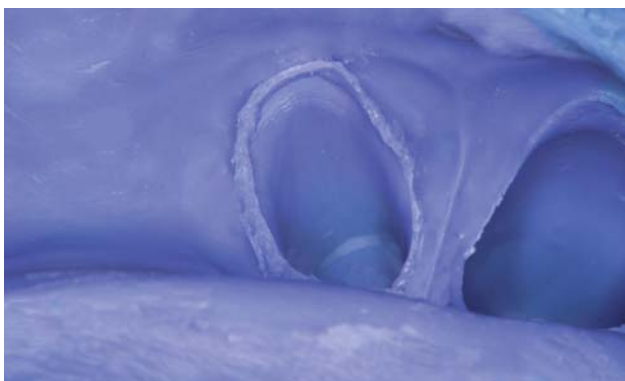


Fig. 5 and 6: Crisp details produced by Identium®.